

*

%6

)

67 (%2.95)

53-7

29.3

(

7

11

(23.88)

16

(%76.11)

51

(18)

(%80.39)

%25

(%70.8)

%53.73

%5.97

% 33.7

) %58.2

)

(% 2.6

(

((- -)) :

Study of Empty Sella Syndrome in Al-Assad University Hospital

Younes Mohammed Kabalan *

Abstract

The empty sella syndrome (ESS) is an asymptomatic radiological syndrome, affecting 6% of post-menopausal women and can be seen in all ages.

We studied subjects given the diagnosis of ESS, among patients admitted to the division of endocrinology. The number of patients with primary ESS was 67 (subjects with secondary ESS were excluded). Average age was 29.3 years with a range of 7-53. Youngest female was 11 yrs, youngest male was 7 yrs. As for sex distribution, it was predominantly female- 51 females (76.11%), 16 males (23.88%).

Ten patients with ESS (under 18 years) presented with growth retardation, five of whom had ectopic neurohypophysis, with dysgenesis of adenohypophysis and empty sella on MRI.

Obesity was present in 80.39% of women, and galactorrhea in 70.8%. whereas among males obesity was seen in 25%. Headache was present in 53.73% of the total cohort.

The results were similar with other studies in many respects, such as a wide age spectrum including children, and the occurrence of diabetes insipidus in 5.97%.

The results of our study were discordant with other studies with respect to hyperprolactinemia which reached 58.2% in our study (in other studies did not exceed 33.7%). No concurrent cases of secretory pituitary adenomas were found (studies refer to an incidence of acromegaly and Cushing's syndrome in 2.6% of ESS for each). We did not record CSF rhinorrhea nor were visual disturbances seen in our cohort. Patients received symptomatic treatment and none were referred to surgery.

Key wards: ESS Hyper-prolactinaemia - Headache

* Ass. professor of Medicine, Dept. of Internal Medicine- Faculty of Medicine, Damascus University

:

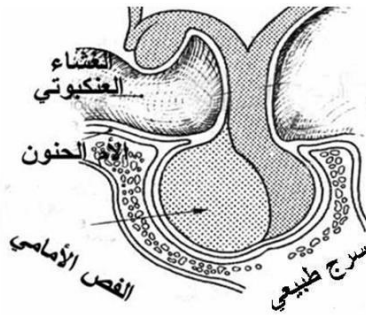
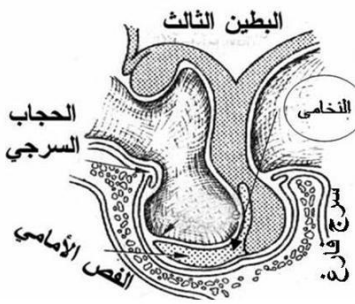
%100

3 1.2 -1.1

(1)

3، 2، 1

6، 5، 4،



1

.9 %5.5

:

7

2

% 80 (1:5= :)

49-40

2004

2001

%90

67

8، 6، 5،

%31

%10

:

....

TSH-FT4- :

ACTH- CORT-FSH- LH-
ESTRADIOL-
TESTOSTERON-PRL-GH

▪)

(...

:

▪

:

40

29.3

7)

11

(53

4

(2270)

7

(%2.95)

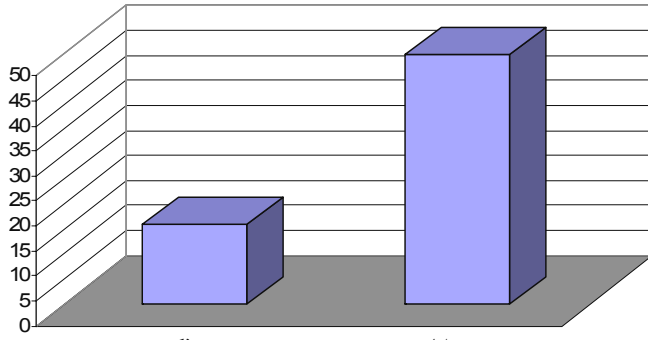
1

16

(%76.11)

51

(23.88)



(1)

2

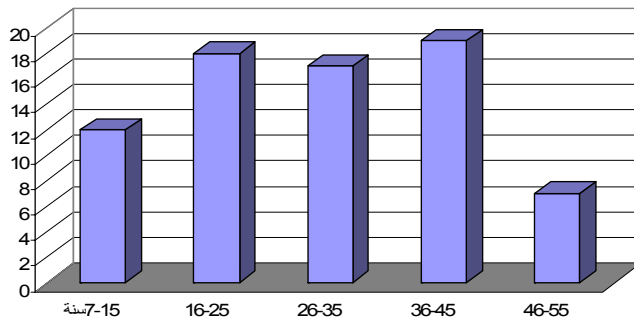
9

10

E Cacciari

11

Bologna



(2)

11

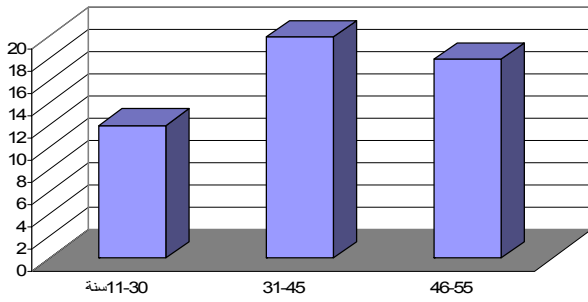
3

45

(%32.29) 18

) 45-20 32

(%62.74

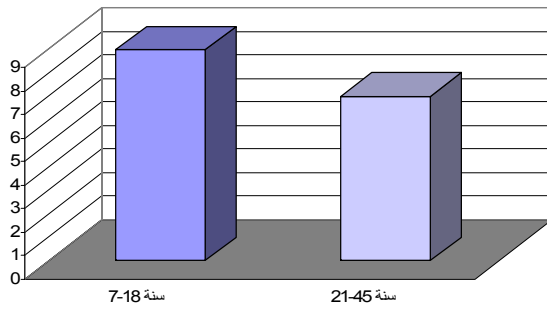


(3)

(%56.25)

(4)

18-7



(4)

) 74 -66
(%80.39)
(%70.8 (1)

%25) 4
(%80.39)
% 65.67 (9) (18
%53.73

17
(5\10± 60\90)

11 10
7

% 14.92
2)

-5)

.¹² (% 16

11

47

10

()

158)

(1)

18.29= BMI

45

(² /

30-24)

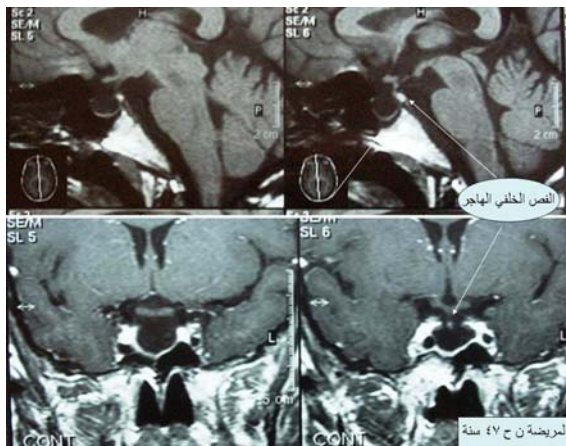
(53-

()

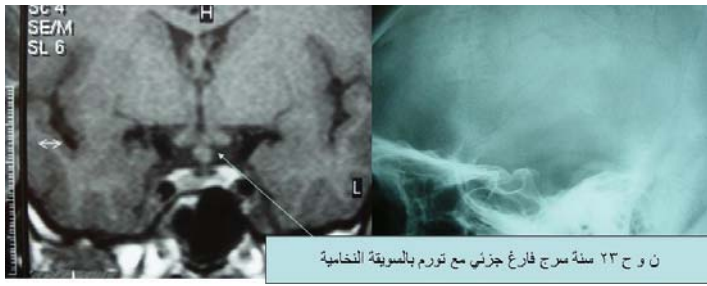())

(1.001

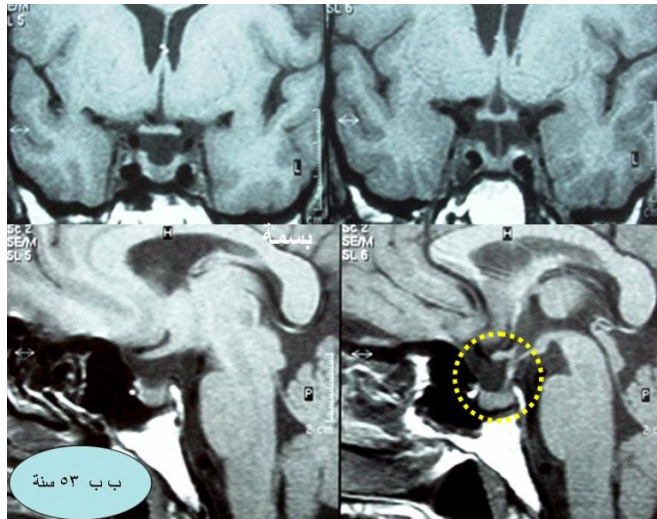(2)



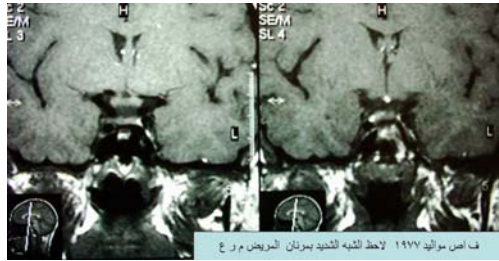
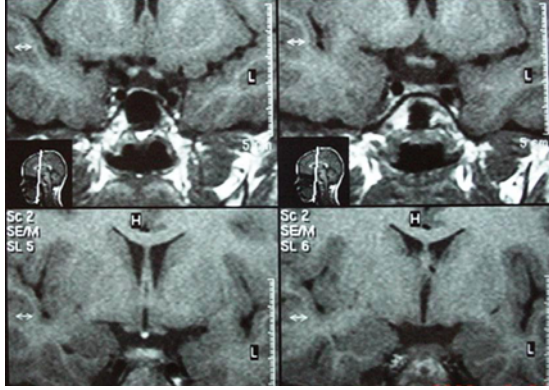
(1)



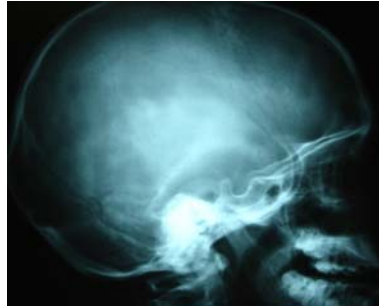(2)

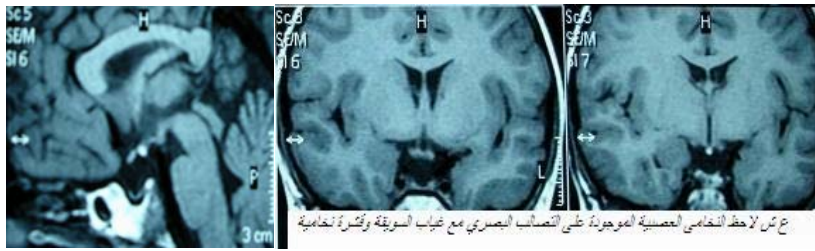

م. ر. ع مواليد ١٩٩٢ الوزن ٢٠ كغ - الطول ١١٨ سم -
TSH= 4.12, FT4=0.56, PRL=48, LH=0.1, FSH=0.2, GH=1.4, 2.02, 3.1, 2.9
لاحظ الفص الخلفي المتصلب بالتهناب البصري -و غياب السويقة وسوء تصنع الخناسي



ف. ا. م مواليد ١٩٧٧ لاحظ التشمع الشديد بمونان المبيض م ر ع





¹³ 1992 Gallardo E			
	%65.67	67/44	
	%80.39	51/41	
	%25	16/4	
%69.7	%53.73	67/36	
%34.2	لا يوجد		
%11.8	لا يوجد		
* %55	%70.58	51/36	
	%23.52	51/12	(51\12)
	%15.68	51/8	(51\8)
	%7.46	67/5	(67\5)
	%31.25	16/5	16\5
	%25.37	67/17	
	% 11.94	67/8	
	%5.97	67/5	
	%14.92	67/10	
	%7.46	67/5	
	%13.43	9	

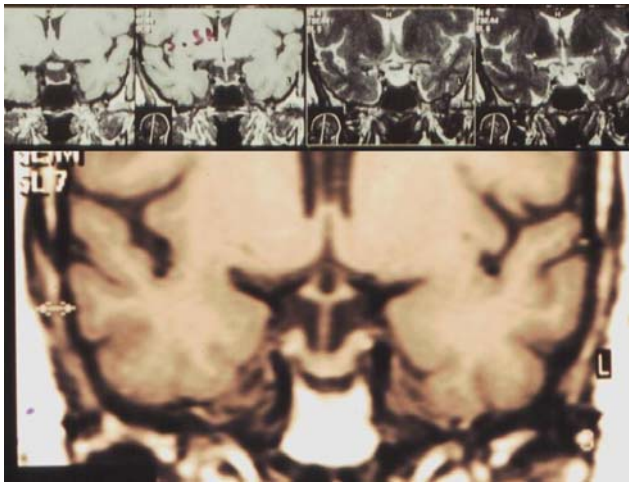
*%55

:

(%74.26)

.(%7.46)

6



%53.73 : .1

%70

: .2

) %20

(
)

(

:

%80.39

) % 58.2

% 33.7

(2)

(3)

:

Buchfelder 14 1989	Gallardo 13 1992	() 2005	
%32.7	%31.6	%58,2	()
	% 2.6	لا يوجد	
	%4	لا يوجد	
%5.6	%15	%7.46	
%7.75			
%9.6			
%5.8			
%25.5		%14.92	
	%2.6	%5.97	

(2)

	**%58.2	PRL
%7.46		GH
%7.46		TSH
%7.46		FT4
%22.38	%8.95	FSH
%22.38	%8.95	LH
%7.46		ACTH
%7.46		CORT

(3 + 36) 39 **

(3)

•

%5.97

14

% 14.92

%48

17

11 8 1

. %2

:

❖ %15)

1 (

❖

❖

)

❖

❖

(

)

(

.16

CSF

. CSF

•

•

•



:

.17

%50

.

References

1. Bjerre P. The empty sella : A reappraisal of etiology and pathogenesis. *Acta Neurol Scand* 1990; 130 (Suppl): 1-25
2. Schaeffer JP: Some points in the regional anatomy of the optic pathway with special reference to tumors of the hypophysis cerebri and resulting ocular changes. *Anat Rec* 28:243--279, 1924.
3. Empty Sella Syndrome. *Journal, Indian Academy of Clinical Medicine* Vol. 2, No. 3 July-September 2001
4. Busch W. Die morphologie der sella turcica and ihre beziehungen zur hypophyse. *Virebowski Arch* 1951; 320: 437
5. Kaufman B: The "empty" sella turcica--a manifestation of the intrasellar subarachnoid space. *Radiology* 90:931--941, 1968 [[MedLine](#)]
6. Bonneville JF, Dietmann JL. Intrasellar pathology. In: *Radiology of the Sella turcica*. Springer Verlag, New York 1981; 89-126.
7. Diagnosis and Treatment of pituitary tumors. Kohler PO, Ross GT. (Ed) *Excerpta Medica* Amsterdam. 1973; 176-206.
8. Neelon FA, Goree JA, Lebovitz HE. The primary empty sella: clinical and radiographic characteristics and endocrine functions. *Medicine* 1973; 52: 73-92.
9. Nagata K, Joshita H, Matsui T, Kaizu H, Ishikawa T, Shigeno T, Asano T: Primary Empty Sella Syndrome Caused by an Abnormal Dilatation of the Optic Recess. *Surg Neurol* 31: 323-329, 1989
10. Ammar A, Al-Sultan A, Al-Mulhim F, Al Hassan A Y: Empty sella syndrome: does it exist in children. *J Neurosurg* 91: 960-963, 1999
11. E Cacciari *et al*, **Empty sella** in children and adolescents with possible hypothalamic- pituitary disorders *Journal of Clinical Endocrinology & Metabolism*, Vol 78, 767-771
12. Diabetes: An International, Epidemiologic Focus, Zachary T. Bloomgarden, MD Mount Sinai Medical School, [18th International Diabetes Federation Congress](#) August 24 - 29, 2003, Paris, France

-
13. Gallardo E, Schachter D, Caceres E, et al: The empty sella: results of treatment in 76 successive cases and high frequency of endocrine and neurological disturbances. *Clin Endocrinol* 37:529--533, 1992
 14. Buchfelder M, Brockmeier S, Pichl J, et al. Results of dynamic endocrine testing of hypothalamic pituitary function in patients with primary 'empty' sella syndrome. *HormMetabRes* 1989;21:573-576.
 15. Hung W, Fitz CR: The primary empty-sella syndrome and diabetes insipidus in a child. *Acta Paediatr* 81:459--461, 1992
 16. Olson DR, Guiot G, Derome P. The symptomatic empty sella: Prevention and correction via transphenoidal approach. *J Neurosurg* 1972; 37: 533-46.
 17. Pocecco M, De Campo O, Marinoni S et al. High frequency of empty sella syndrome in children with growth hormone deficiency. *Helv Paediatr Acta* 1989; 43: 295-301.

.2005/11/13:

.2006/5/8 :